



## Acute Toxicity and Histological Alterations in the Gills and Liver of African Catfish (*Clarias gariepinus*) Exposed to J-Furan

\*<sup>1</sup>Ezekiel, B., <sup>2</sup>Yaji, A.J., <sup>2</sup>Kefas, M., & <sup>3</sup>Bala, B.

<sup>1</sup>Department of Fisheries Technology, Federal College of Horticulture Dadin Kowa, Gombe State

<sup>2</sup>Department of Fisheries, Moddibbo Adama University Yola, Adamawa State

<sup>3</sup>Department of Biological Sciences, Gombe State University, Gombe State

\*Corresponding author email: [buzyezekiel@gmail.com](mailto:buzyezekiel@gmail.com)

### Abstract

Carbofuran, a widely used insecticide found in products like J-Furan, is known for its effectiveness in agriculture—but its impact on aquatic life is a growing concern. The study assessed the acute toxicity of J-Furan on the liver and gills of juvenile freshwater African catfish (*Clarias gariepinus*). The species was subjected to varied insecticide concentrations for 96 hours, and histological examinations were carried out to see the effects on the hepatic tissue. The results indicated that as the insecticide concentrations increased, the damage to the liver and gills became severe. The liver has been the major organ for detoxification, showed Cytoplasmic vacuolation, hemorrhagic areas, inflammatory cell necrosis, the disintegration of the hepatocyte cell membrane and oozing of cytoplasmic content, mononuclear cell infiltration, hepatocyte fusion, vascular congestion, degeneration of hepatocytes and cellular degeneration while the gills critical for breathing developed various degree of structural deformities like vacuolated gill arch cells, dilated secondary inter-lamellar space, secondary lamellar necrosis, occlusion in secondary inter-lamellar space, fusion, and shortening of secondary lamellae, vacuolization in the epithelium, increased in secondary inter-lamellar space and shortening and fusion in secondary lamellae. This study reveals that even short-term exposure to carbofuran can have damaging effects, highlighting the need for effective control, regulation, and safer use of agricultural chemicals near aquatic environments.

**Keywords:** Acute, Pesticide, J-Furam, Toxicity, Agriculture

### Introduction

Carbamates are commonly used worldwide as insecticides, although having medicinal properties. They act as acetylcholinesterase inhibitors and can temporarily block the breakdown of acetylcholine. In addition, carbamates are known as endocrine-disrupting substance which can interfere with the hypothalamic–pituitary–testicular axis, an important pathway for normal male reproductive function. This can lead to male reproductive disorders. (Moreira *et al.*, 2022). Carbofuran (2, 2-Dimethyl-3H-1-benzo furan-7-yl), commonly referred to as CF, is a systemic pesticide that infiltrates plants and acts as poison to insects upon ingestion. The continuous used of CF in agriculture lead to environmental deterioration of food, water, and air, posing adverse effects to both human and animal health. Studies has shown that the introduction of diverse substances into water bodies due to manmade activities alters the quality of water bodies thereby leading to degradation of habitat and the availability of food which pose a threat to the local availability of healthy fish (Bala *et al.*, 2019). Literatures have also revealed that physiological alterations in aquatic organism especially fish can serve as bio-indicator of environmental stressors in the aquatic eco-system (Elarabany & Bahnasawy 2019). Pesticides eventually get into water bodies through run-off, aerial spray and while cleaning the used containers thereby leading to poisoning of the eco-system (Esenowo *et al.*, 2022). Likewise, j-furan introduced into aquatic eco-system may be responsible to hormone-related ailment such as reproductive mal-function thereby altering the normal functioning of progesterone, testosterone, estrogens, prolactin, and luteinizing hormones or result to cancers due to its adverse effects, its penetrability into mammalian tissues and its endocrine disrupting

1 Cite this article as:

Ezekiel, B., Yaji, A. J., Kefas, M., & Bala, B. (2025). Acute toxicity and histological alterations in the gills and liver of african catfish (*clarias gariepinus*) exposed to j-furan. *FNAS Journal of Scientific Innovations*, 6(4), 1-10.

ability (Rouachdia et al., 2022). Meanwhile, there is a possibility of toxicity of j-furan pesticide exposure to non-target organisms, especially fish, and thus lead to adverse effects on health and survival. Thus, anthropogenic use of these chemicals may cause harmful effects on the natural environment. An aquatic ecosystem is more sensitive to this exposure to toxic contaminants. Henceforth, the knowledge of the toxicity of this insecticide to *C. gariepinus* can give us an insight into its toxicity towards other living organisms. The implication of this can be well understood if j-furan has toxic effects on juveniles of African catfish.

## Materials and Methods

### Preparations of Test Solutions

An insecticide that contains carbofuran as its active ingredient (with the trade name J-Furan) was purchased at a reputable Agrochemicals and Farming equipment, in Yola. It has a formulation percentage of 3% G; manufactured by Jubaili Agrotec Limited, and has the manufacturing and expiry dates of December 2022 and December 2024 respectively. 50ml of distilled water was used to dissolve 20g of the pesticide (j-furan) before use.

### Pilot Test

After the acclimation period, trial tests were carried out using the toxicant j-furan by exposing ten surviving fish to each of the test solutions prepared to obtain information about the appropriate range of concentrations to be used in the main tests. Borehole water was used throughout the study. Ten juveniles of *Clarias gariepinus* were randomly selected and transferred into 70 litres capacity experimental bowls containing 20 litres of water with replicates. Nets were used to cover the bowls to prevent fish from jumping out. Ten fish were also added in a control bowl and maintained without toxicant. The feeding was suspended one day prior to and during exposure time of 96 hours. At the 24, 48, 72, and 96 hours of the exposure time, fish mortalities were observed and recorded across the graded concentrations and the dead fish removed immediately from the test solution to avoid fouling the media. The concentration ranges of the toxicants used for the definitive tests were determined from the trial (pilot) test.

### Acute Toxicity Test

From the observations made from the pilot test, test solutions comprising five concentrations of j-furan (20 mg/L, 26 mg/L, 32 mg/L, 38 mg/L, and 44 mg/L) were prepared. A total of three hundred and sixty (360) surviving juvenile *Clarias gariepinus* (mean weight of  $10.4 \pm 0.28$ g and mean total length of  $12.8 \pm 0.26$ cm) which were acclimatized to laboratory conditions were distributed into thirty-six (36) plastic transparent containers containing ten fish each. The fish were exposed to six treatments as presented above and a control (0.00 mg/L) for 96 hours, the treatments were triplicated. The rest of the procedure is as in the pilot test.

**Collection of samples:** The liver of the dissected test fish that died from each treatment and the control group were collected. To remove/harvest the liver, scissor was used to cut from below the operculum on the ventral position through the anal pore towards the tail. The gut was removed and the liver was carefully held with forceps while linking tissues were cut out.

**Fixation:** The liver tissues removed from the fish were immediately preserved in 10 % formalin in individual sterile bottles to prevent spoilage. The samples collected were taken to Federal Teaching Hospital Gombe, Gombe State for histological analysis.

**Dehydration:** To ensure the hardening of the liver tissues through dehydration, the liver tissues were put in various grades of alcohol ranging from 70 %, 80 %, 90 %, and 100 % for about 2 to 4 hours each so as to remove its water content and then into xylene for some hours.

**Embedding:** The liver samples were embedded with paraffin wax at a melting point between 40-70 °C and an embedment mould in order to solidify the samples.

**Sectioning:** A microtome was used to section each sample into thin slices. By fastening the liver tissues to the microtome holder, they were carefully cut after trimming. This is to make floatation easier.

**Floatation:** The liver tissues were floated out by picking with a forceps and floating them in water at 45 °C to unfold the tissue. The floating tissues were then picked from the water by immersing a slide into the water and then the tissues were drawn out after they adhered to the slide. The tissues were then dried in an incubator overnight at a temperature of 37 °C.

**Staining:** To facilitate microscopic examination and micrographs, the wax was removed from the tissues using two changes of xylene for two minutes each. The tissues were then hydrated in ethanol of 95 %, 80 %, and 70 % concentration grades for 2-3 minutes for each change, washed in water for five minutes, and then stained with Harris Haematoxylin for 5- 7 minutes. The stained tissues were washed in water again. The tissues were briefly differentiated in 1 % acid alcohol and blue Scott de-chlorinated water for five minutes. The tissues were briefly washed in water and then counterstained in 1 % aqueous Eosin for six minutes, washed briefly in water, and dehydrated in 70 % alcohol for two minutes, 80 % and 90 % alcohol for three minutes each, then the tissues were put in ethanol for four minutes and absolute xylene for three minutes. It was cleared in xylene after ten minutes and this process was repeated (Akaahan et al., 2016).

**Microscopy:** The tissues were mounted on a LEICA ICC50 HD photomicroscope and the slides were examined and pictures taken to see the various changes in the structural makeup of the tissues.

## Gills

To remove gills from dead fish, a forceps was used to hold the operculum of the fish from the ventral position. A scissor was then carefully used to cut the mouth from both sides and also tissues linked to the gills were cut. Other tissues connected to the gills were cut to allow for easy extraction/harvest of the gill from fish taken from each treatment. The same procedures described for histological assessment of liver tissues (above) were followed in assessing the gills.

## Results

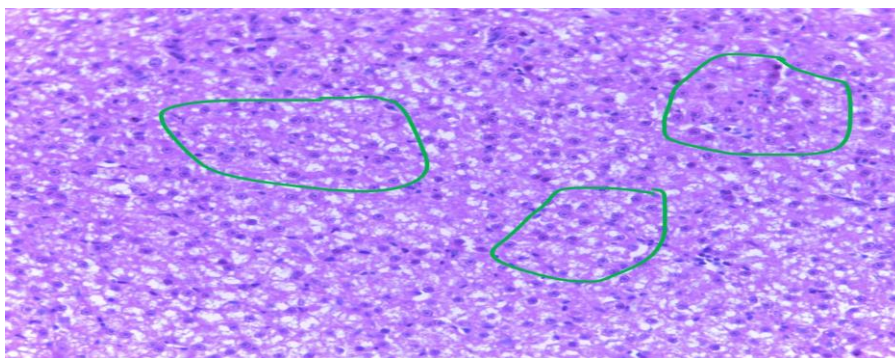


Plate 1: Photomicrographs of *C. gariepinus* liver tissue subjected to 0.00mg/L (control) showing normal liver with Hepatocytes (with a conspicuous nucleus), having abundant, granular and eosinophilic (pink staining) cytoplasm (green cycles)

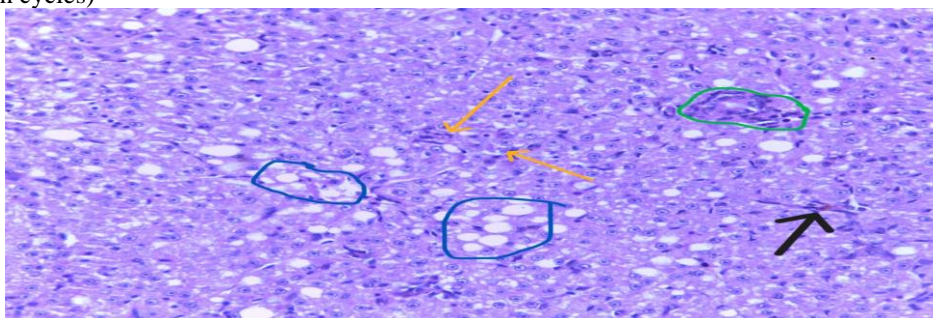




Plate 2: Photomicrographs of *C. gariepinus* liver tissues subjected to 20mg/L of j-furan showing Cytoplasmic vacuolation (blue cycle), hemorrhagic area (black arrow) inflammatory cells (yellow arrows) and necrosis (green cycle)

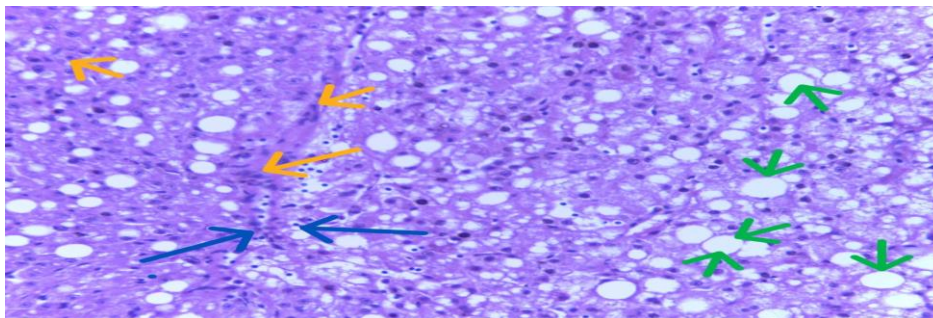


Plate 3: Photomicrographs of *C. gariepinus* liver tissue subjected to 26mg/L of j-furan showing Cytoplasmic vacuolation (green arrow), oozing of cytoplasmic materials and disintegration of hepatocytes cell membrane (blue arrows) and necrosis (yellow arrows)

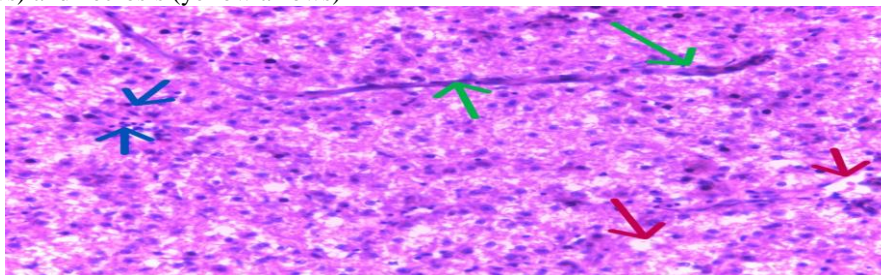


Plate 4: Photomicrographs of liver tissues in juvenile *C. gariepinus* subjected to 32mg/L of j-furan showing Cytoplasmic vacuolation (red arrow), mononuclear cell infiltration (blue arrow) and Melano-macrophages center (green arrows)

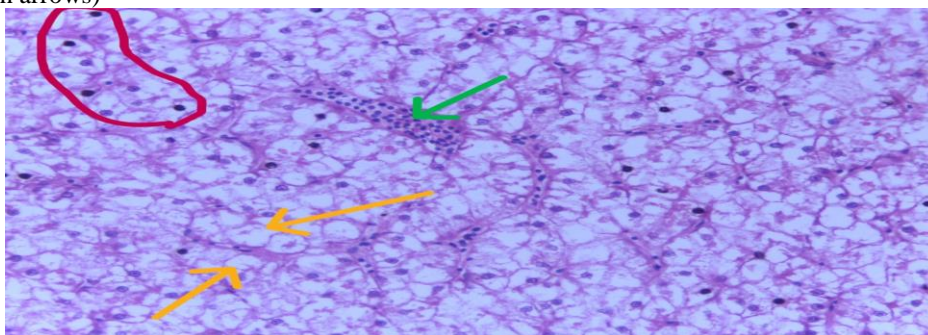



Plate 5: Photomicrographs of liver tissues in juvenile *C. gariepinus* exposed to 38mg/L of j-furan showing mononuclear cell infiltration (green arrow), Hepatocytes fusion, (red cycle) visible central vein and vascular congestion and degeneration of hepatocytes (Yellow arrows)



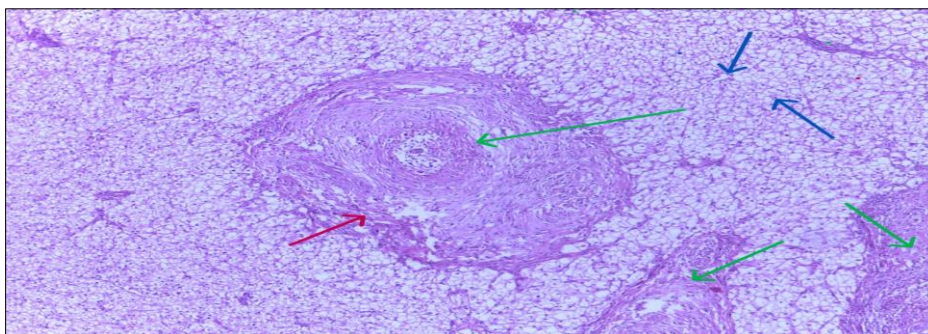


Plate 6: Photomicrographs of liver tissues in juvenile *C. gariepinus* exposed to 44mg/L of j-furan showing Melanomacrophages center (green arrows), vascular congestion (red arrow) and cellular degeneration (blue arrows)

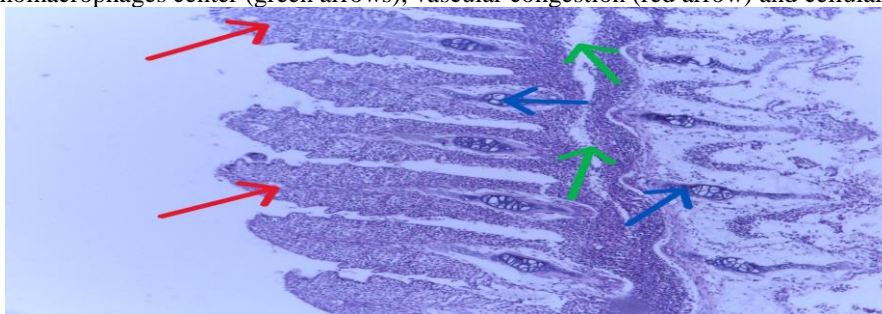


Plate 7: Photomicrographs of gill tissues in juveniles *C. gariepinus* introduced to 0.00mg/L (control) showing: secondary and primary lamellar (red arrow), Gill arch cells (blue arrows) and Primary lamellae (Green arrows)

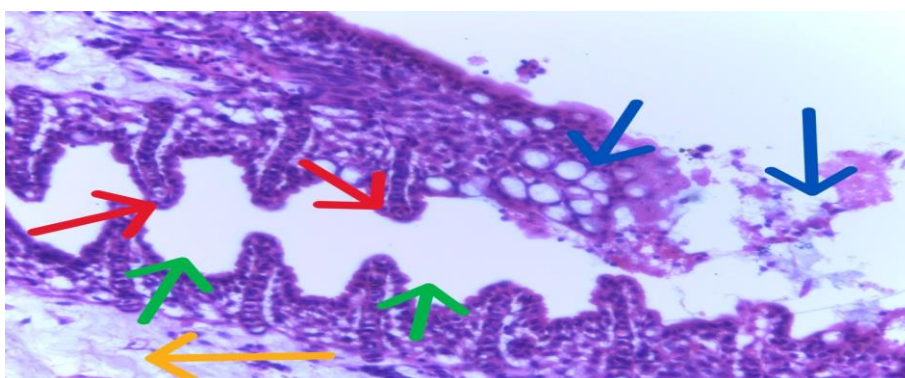


Plate 8: Photomicrographs of gill tissues in juvenile *C. gariepinus* introduced to 20mg/L of J-furan showing: vacuolated gill arch cells (yellow arrow), dilated secondary inter-lamellar space (green arrows), and secondary lamellar necrosis (blue arrows)

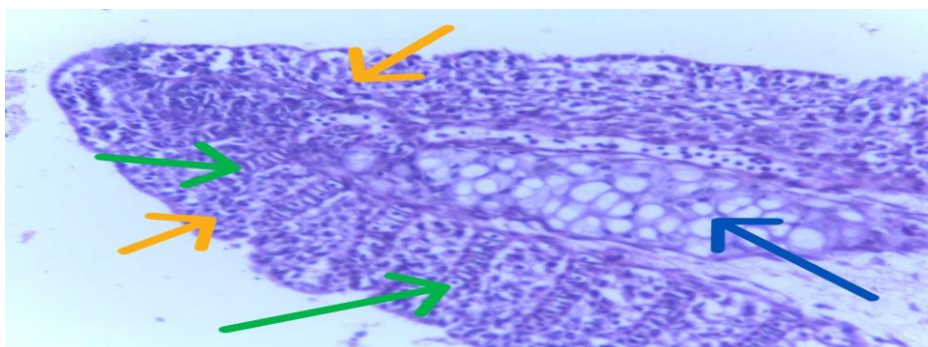




Plate 9: Photomicrographs of gill tissues in juvenile *C. gariepinus* exposed to 26mg/L of j-furan showing: occlusion in secondary inter-lamellar space (green arrow), primary lamellae (Blue arrow) and Pilaster (Pillar) cells (yellow arrows)

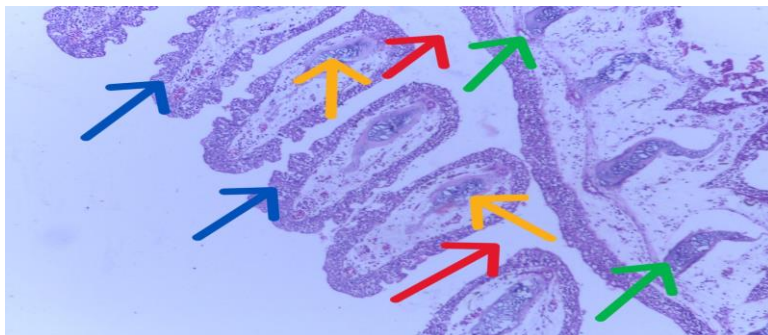


Plate 10: Photomicrographs of gill tissues in juvenile *C. gariepinus* subjected to 32mg/L of j-furan showing: fusion and shortening of secondary lamellae (blue arrows), Gill arch cells (green arrows), primary lamellae (yellow arrows), vacuolation (red arrows)

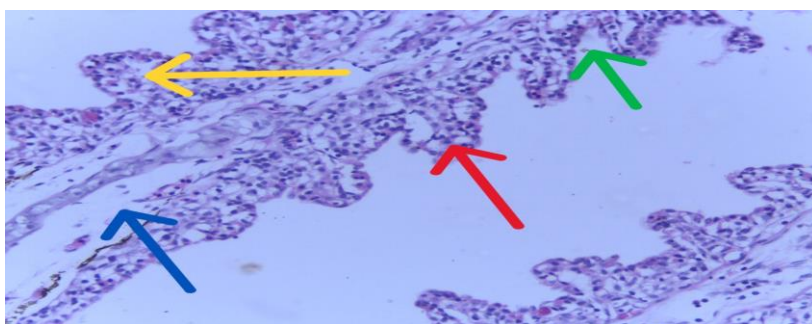


Plate 11: Photomicrographs of gill tissues in juvenile *C. gariepinus* exposed to 38mg/L of j-furan showing: vacuolization in the epithelium (blue arrow), increased in secondary inter-lamellar space (green arrow) and Pilaster (Pillar) cells (Yellow arrow).

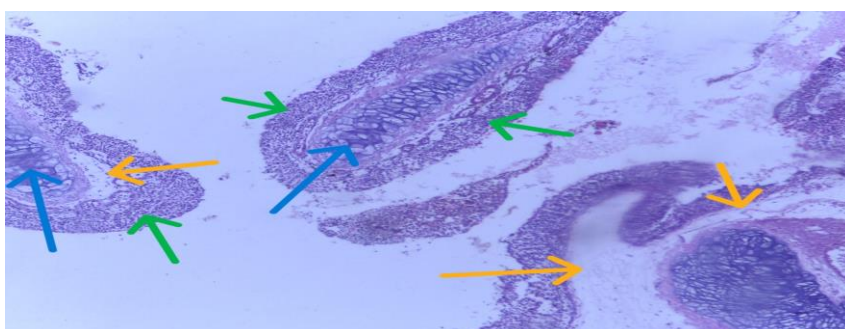


Plate 12: Photomicrographs of gill tissues in juvenile *C. gariepinus* exposed to 44mg/L of j-furan showing: vacuolization in the epithelium (yellow arrow), occlusion in secondary inter-lamellar space, shortening and fusion in secondary lamellae (green arrows), Primary lamellae (blue arrows)

## Discussion

### Effects of Acute Concentrations of J-furan on Liver Histopathology of Juvenile *Clarias gariepinus*

The severity of injury to organs is due to the nature, concentration, mode of action, and exposure time of toxicants to fish. Removal of xenobiotics and other toxic substances and metabolism is the primary responsibility of the liver (Bala *et al.*, 2023). The liver can reduce the intensity of the harmful substances, but its ability and capability can be

overpowered by the gradual increase in concentrations of these chemicals and may lead to histological damage (Prudencio et al., 2023). Hepatic alterations in fish are used as indicators of toxicants in an aquatic environment (Tashla et al., 2018).

The liver tissues of juvenile *C. gariepinus* exposed to acute toxicity of j-furan for 96 hours showed varying degrees of Cytoplasmic vacuolation, hemorrhagic areas, inflammatory cell necrosis, the disintegration of the hepatocyte cell membrane and oozing of cytoplasmic content, mononuclear cell infiltration Melano-macrophages centre, Hepatocytes fusion, vascular congestion, degeneration of hepatocytes and cellular degeneration (Plate 2-6) compared to the control group (Plate 1) which showed normal liver tissue with Hepatocytes (with a conspicuous nucleus), having abundant, granular and eosinophilic (pink staining) cytoplasm.

The changes recorded in this study could be related to the acute concentration effects of this insecticide in the liver tissues which might lead to nuclear condensation, vacuolation, and necrosis (Davies et al., 2022; Wolf & Wheeler, 2018). The studied fish could not regenerate new liver cells and this could be related to the toxic alteration of j-furan that has led to necrosis and vascular degeneration (Wolf & Wheeler, 2018). The severe effects of the increased concentrations of the insecticide could be responsible for the necrosis and degeneration of liver hepatocytes and the hepatic tissue of the exposed fish (Davies et al., 2022; Saha et al., 2021). Furthermore, the liver tissue necrosis and degeneration of vascular cells reported in this study could be related to the rigorous functions required by the exposed fish to detoxify the toxic effects of the insecticide on the liver (Adewumi et al., 2018; Davies et al., 2022; Shah & Parveen, 2022). Sani et al. (2020) opined that fish subjected to harmful substances experience certain forms of preternatural conditions such as abnormally shaped hepatocytes, vacuolation of cytoplasm, vacuolation of nuclear, nuclear degeneration, and focal necrosis in the fish livers.

The presence of vacuolations in the liver tissues was attributed to lipid accumulation within hepatocytes, resulting in the formation of lipidic vacuoles. This vacuolization may reflect a disruption in the balance between the synthesis and secretion of substances into circulation (Prudencio et al., 2023). Necrotic regions observed in the hepatic tissues are likely linked to the intense detoxification activity by the liver, which occurs as the fish attempt to eliminate harmful substances. Similar observations were recorded by Okechukwu et al. (2022), Manimekalai et al. (2022), and Cheikyula et al. (2022). The inability of liver cells to regenerate effectively might have contributed to the occurrence of necrosis. Moreover, nuclear shrinkage and pyknosis were evident, indicating cellular degeneration, as also documented by Okechukwu et al. (2022).

Hemorrhagic areas and sinusoidal dilations observed in this study may have resulted from the liver being overburdened with detoxification processes, which places stress on the blood vessels supplying the liver. This excessive blood flow can obstruct hepatic sinusoids, leading to circulatory impairment (Prudencio et al., 2023). In extreme cases, these sinusoids may rupture, causing haemorrhage, as observed by Maurya et al. (2019). As an adaptive response to this increased pressure, the hepatic sinusoids may become dilated to facilitate blood circulation, a finding also reported by Agbohessi et al. (2015) in *C. gariepinus* exposed to agricultural pesticides. The histopathological changes observed in this study are consistent with findings by Adewumi et al. (2018), Davies et al. (2022), Sula et al. (2020), and Singh et al. (2019).

### Effects of Acute Concentrations of J-furan on Gills Histopathology of Juveniles *Clarias gariepinus*

Gill histology serves as a vital indicator of toxicant exposure and is a reliable method for assessing aquatic environmental pollution (El-Houseiny et al., 2022). In *C. gariepinus*, the gills are the primary organs exposed to aquatic toxicants, and any change in water quality can compromise their function (Kenan et al., 2022). Since the gills are responsible for respiration and osmoregulation, any structural damage can result in respiratory distress or hypoxia (Yasser & Naser, 2011). The control group (Plate 7) showed no histopathological abnormalities. However, in fish exposed to various concentrations of J-Furan, several alterations were observed in the gills, including vacuolation of gill arch cells, dilated secondary interlamellar spaces, necrosis of secondary lamellae, occlusion of interlamellar spaces, fusion and shortening of secondary lamellae, epithelial vacuolization, and other structural deformities (Plates 8–12) compared to the control group.

These histopathological changes reflect significant damage to the gill architecture, which is indicative of toxicant-induced stress and may impair respiratory efficiency. Observed alterations such as necrosis, lamellar vacuolization,

shortening, fusion, lamellar edema, and hyperplasia are consistent with those reported by Davies et al. (2022). The fusion of secondary lamellae may result from increased production of mucus and epithelial cells, potentially acting as a defensive barrier rather than being a direct toxicant effect (Doherty et al., 2011). Ojogu et al. (2017) also noted that the proliferation of mucus cells enhances mucus secretion which aids in removing trapped toxicants from gill surfaces.

Prolonged exposure may deplete these mucus reserves, leading to the erosion of superficial epithelial cells (Zulkipli et al., 2021). Other observed responses, such as lamellar fusion, edema, and reduced interlamellar space, are considered defensive strategies aimed at increasing the distance between the external environment and the bloodstream, thus minimizing toxicant entry (Korkmaz & Orun, 2022; Kenan et al., 2022). Additionally, fusion and shortening of lamellae might result from epithelial hypertrophy and hyperplasia, reflecting the fish's physiological attempt to reduce permeability to harmful substances (Kenan et al., 2022). Comparable histological damage has been documented in other fish species such as *Chanos chanos* (Kumar et al., 2016), *Oncorhynchus mykiss* (Altinok & Capkin, 2007), *Channa punctatus* (Sarma et al., 2011), and *Clarias gariepinus* (Islam et al., 2021). Therefore, the severity of histopathological changes in the gills of *C. gariepinus* in this study was more pronounced at higher concentrations of J-Furan, signifying a dose-dependent toxic effect.

## Conclusion

This study indicates that acute concentrations of J-Furan (carbofuran based insecticide) on *Clarias gariepinus* demonstrate dose-dependent histological changes such as cytoplasmic vacuolation, hepatocellular necrosis, inflammatory cell infiltration, vascular congestion, fusion of hepatocytes, and the appearance of melano-macrophage centre in the liver; while the gills show histological alterations, including vacuolation of gill epithelial and arch cells, necrosis and fusion of lamellae, occlusion of inter-lamellar spaces, and deformation of pillar cells. These changes suggest impaired liver function, disruption of metabolic processes, activation of immune responses to toxicant, respiratory distress and impaired osmoregulatory functions in the exposed fish.

## Recommendation

Considering the histopathological changes observed in juvenile *Clarias gariepinus*, it is recommended that environmental regulatory agencies integrate these toxicity thresholds into water quality standards. This would aid in setting safe discharge limits for J-Furan to minimize ecological risks in an aquatic environments.

## References

- Adewumi, B., Ogunwole, G.A., Akingunsola, E., Falope, O.C., & Eniade, A. (2018). Effects of sub-lethal toxicity of chlorpyrifos and DD force pesticides on haematological parameters of *Clarias gariepinus*. *International Resource Journal Public and Environmental Health* 5 (5): 62-71.
- Agbohessi, T.P., Imorou, T.I., Atchou, V., Tonato, R., Mandiki, S.N., & Kestemont, P. (2015). Pesticide Used in Cotton Production Affect Reproductive Development, Endocrine Regulation, Liver Status and Offspring Fitness in African Catfish *Clarias gariepinus* (Burchell, 1822). *Comp. Biochem. Physiol. Part C Toxicol. Pharmacol.*, 167, 157–172.
- Akaahan, T.J., Akogwu, S.A., & Olabanji, F.M. (2016). Bioassay of the Ultrastructural characteristics in the kidney and liver of the African catfish, *Clarias gariepinus* juveniles exposed to graded concentration of zinc. *International Journal of Environment, Agriculture and Biotechnology*. 1(3):448-456.
- Altinok, I., & Capkin, E. (2007). Histopathology of Rainbow Trout Exposed to Sublethal Concentrations of Methiocarb or Endosulfan. *Toxicol. Pathol*, 35, 405–410.
- Bala, B., Azua, E.T., & Akaahan, T.J. (2019). Haematological studies of African catfish (*Clarias gariepinus* Burchell, 1822) exposed to sublethal concentrations of atrazine. *International Journal of Fisheries and Aquatic Studies*. 7(3): 256-260.
- Bala, B., Azua, E.T., Yusuf, M.A., & Ezekiel, B. (2023). Acute Toxicity, Behavioural and Histological Changes in Juvenile *Clarias gariepinus* Exposed to Atrazine. *Journal of Aquatic Sciences* 38(2): 195-211. DOI: <https://dx.doi.org/10.4314/jas.v38i2.16>
- Cheikyula, J.O., Umaru, J.A., & Ategha, A. (2022). changes in the liver of African catfish, *Clarias gariepinus* juveniles exposed to sub-lethal concentrations of glyphosate. *Journal of Research in Forestry, Wildlife and Environment*, 14(2): 39 – 44.



- Davies, I.C., Efekemo, O., & Evelyn, G.A. (2022). Quantal Response and Histopathological Effects of Sub-lethal Concentrations of a Selected Oilfield Chemical on African Catfish (*Clarias gariepinus*). *Journal of Biology and Genetic Research* .Vol 8. No. 2 23-41
- Doherty, T. (2011). Effect of environmental pesticides on organisms *Indian Journal of Experimental Biology*, 45:432-8.
- Elarabany, N., & Bahnasawy, M. (2019). Toxicological research comparative and interactive biochemical effects of sub-lethal concentrations of cadmium and lead on some tissues of the African Catfish (*Clarias gariepinus*). *Toxicology Resources* 35(3):249–255.
- El-Houseiny, W., Anter, R.G.A., Arisha, A.H., Mansour, A.T., Safhi, F.A., Alwutayd, K.M., Elshopakey, G.E., Abd El-Hakim, Y.M., & Mohamed, E.M.M. (2023). Growth Retardation, Oxidative Stress, Immunosuppression, and Inflammatory Disturbances Induced by Herbicide Exposure of Catfish, *Clarias gariepinus*, and the Alleviation Effect of Dietary Wormwood, *Artemisia cina*. *Fishes*, 8, 297. <https://doi.org/10.3390/fishes8060297>
- Esenowo, I.K., Nelson, A.U., Ekpo, N.D., Chukwu, M.N., Akpan, A.U., Ugwumba, A.A.A., Ugwumba, A.O., Alimba, C.G., Effiong, M.U., Udoidung, N.I., Ukpog, N.C., Ogidiaka, E., Adeyemi-Ale, O.A., & Oboho, D.E. (2022). Effects of Acute Exposure to Chlorfenapyr on Hepatic Enzyme Activities and Serum Lipid Profile of African Catfish, *Clarias gariepinus* (Burchell 1822). *World Journal of Applied Science and Technology*, 14 (1b) 86 - 93 <https://dx.doi.org/10.4314/WOJAST.v14i1b.86>
- Gera, N., Kiran, R., & Mahmood, A. (2011). Carbofuran administration induces genotoxic effects in epithelial cells across crypt-villus axis in rat intestine. *Pesticide Biochemistry and Physiology*, vol. 100, no. 3, pp. 280-283. <http://dx.doi.org/10.1016/j.pestbp.2011.04.013>.
- Islam, M.A., Amin, S.M.N., Brown, C.L., Juraimi, A.S., Uddin, M.K., & Arshad, A. (2021). Determination of Median Lethal Concentration (LC50) for Endosulfan, Heptachlor and Dieldrin Pesticides to African Catfish, *Clarias gariepinus* and Their Impact on Its Behavioral Patterns and Histopathological Responses. *Toxics*, 9, 340. <https://doi.org/10.3390/toxics9120340>
- Kenan, E., Gül, N.Ö., Nuh, K., Belda, E., Hüseyin, P., Arzu, D., Mehmet, İ.D., & İbrahim, Ö. (2022). Stress, growth, cytokines and histopathological effects of permethrin in common carp (*Cyprinus carpio*), *Chemistry and Ecology*, DOI: 10.1080/02757540.2022.2032000.
- Korkmaz, N., & Orun, I. (2022). Research of the hematological, antioxidant and histopathological effects of Neemazal-T/S on common carp fish *Cyprinus carpio* (Linnaeus 1758). *Fresenius Environ Bull*. 29(9):7246–7256.
- Kumar, N., Ambasankar, K., Krishnani, K., Gupta, S., Bhushan, S., & Minhas, P. (2016). Acute toxicity, biochemical and histopathological responses of endosulfan in *Chanos chanos*. *Ecotoxicol. Environ. Saf*. 131, 79–88.
- Manimekalai, D., Srinivasan, A., Padmavathy, P., Jawahar, P., George, R., & Arisekar, U. (2022). Acute and chronic toxicity effects of the heptachlor pesticide on tilapia (*Oreochromis mossambicus*): Impact to behavioral patterns and histopathological responses. *Journal of Coastal Research*, 38(5), 999–1010.
- Maurya, P.K., Malik, D.S., Yadav, K.K., Gupta, N., & Kumar, S. (2019). Haematological and histological changes in fish *Heteropneustes fossilis* exposed to pesticides from industrial waste water. *Human and Ecological Risk Assessment: An International Journal*. 25:5, 1251-1278, DOI: 10.1080/10807039.2018.1482736
- Moreira, S., Silva, R., Carrageta, D.F., Alves, M.G., Seco-Rovira, V., Oliveira, P.F., & De Lourdes P.M. (2022). Carbamate Pesticides: Shedding Light on Their Impact on the Male Reproductive System. *International Journal of Molecular Sciences* 23, 8206. <https://doi.org/10.3390/ijms23158206>
- Ojogu, N.A., Annune, P.A., & Okayi, G.R. (2017). Toxicological effects of aqueous extract of piptadeniastrum africanum bark on *Clarias gariepinus* juveniles. *Banat's Journal of Biotechnology*, 8(15), 123-135.
- Okechukwu, I.O., Amarachineke, E.F., & Godwin, N.N. (2022). Combinations of cypermethrin and dimethoate alter behavior, hematology and histology of African Catfish, *Clarias gariepinus* *Environmental Analysis Health and Toxicology* Vol: 37(4),2022-2028. Article ID: e2022028, 11 pages <https://doi.org/10.5620/eaht.2022028>
- Prudencio, A., Laurence, O., Bodelaire, D., Gisèle, H., Ibrahim, I.T., Syaghalirwa, N., Mandiki, M., & Patrick, K. (2023). Comparative assessment of acute toxicity and histological changes in liver of African catfish *Clarias gariepinus* exposed to cotton insecticides, *Journal of Environmental Science and Health, Part B*, 58:1, 31-44, DOI: 10.1080/03601234.2023.2168445.

- Rouachdia, R., Trea, F., Tichati, L., & Ouali, K. (2022). Assessment of biochemical markers and behavior response of non-target freshwater teleost *Gambusia affinis* to carbofuran toxicity. *Applied Ecology and Environmental Research* 21(1):545-559. DOI: [http://dx.doi.org/10.15666/aeer/2101\\_545559](http://dx.doi.org/10.15666/aeer/2101_545559)
- Saha, S., Mukherjee, D., Dhara, K., Pal, P., Chukwuka, A.V., & Saha, N. (2021). Biomarker approach for assessing chronic toxicity of Captan® herbicide using haematological, growth, endocrine and biochemical endpoints in air breathing catfish, *Clarias batrachus*.
- Sani, A., Ahmad, M.I., & Abdullahi, I.L. (2020). Toxicity effects of Kano central abattoir effluent on *Clarias gariepinus* juveniles. *Heliyon*, 6(7), 404-465.
- Sarma, K., Pal, A.K., Sahu, N.P., Dalvi, R.S., Chatterjee, N., Mukherjee, S.C., & Baruah, K. (2011). Acute and chronic effects of endosulfan on the haemato-immunological and histopathological responses of a threatened freshwater fish, spotted murrel, *Channa punctatus*. *Fish Physiol. Biochem.*, 38, 499–509.
- Shah, Z.U., & Parveen, S. (2022). Oxidative, biochemical and histopathological alterations in fishes from pesticide-contaminated river Ganga, India. *Scientific Reports*, 12(1), 1-12.
- Singh, A.K., Rana, K.S., & Sharma, K. (2019). Chromium, nickel and zinc induced histopathological alteration in the liver of Indian common carp *Labeo rohita* (Ham.). *International Archive of Applied Sciences and Technology*, 10(2), 49-55.
- Tashla, T., Žuža, M., Kenjveš, T., Prodanović, R., Soleša, D., Bursić, V., & Puvača, N. (2018). Fish as an important bio-indicator of environmental pollution with persistent organic pollutants and heavy metals. *Journal of Agronomy*, 28.
- Wolf, J.C., & Wheeler, J.R. (2018). A critical review of histopathological findings associated with endocrine and non-endocrine hepatic toxicity in fish models. *Aquatic Toxicology*, 197, 60-78.
- Yasser, A.G., & Naser, M.D. (2011). Impact of pollutants on fish collected from different parts of Shatt Al- Arab River: a histopathological study. *Environ Monit Assess.* 181(1):175–182.
- Zulkipli, S.Z., Liew, H.J., Ando, M., Lim, L.S., Wang, M., Sung, Y.Y., & Mok, W.J. (2021). A review of mercury pathological effects on organs specific to fishes. *Environmental Pollutants and Bioavailability*, 33(1), 76-87.